

# Genome Sequencing Identifies a Basis for Everolimus Sensitivity

Gopa Iyer,\* Aphrothiti J. Hanrahan, Matthew I. Milowsky, Hikmat Al-Ahmadie, Sasinya N. Scott, Manickam Janakiraman, Mono Pirun, Chris Sander, Nicholas D. Socci, Irina Ostrovnya, Agnes Viale, Adriana Heguy, Luke Peng, Timothy A. Chan, Bernard Bochner, Dean F. Bajorin, Michael F. Berger, Barry S. Taylor,† David B. Solit†

A long-standing problem in oncology is the variability of treatment response observed in early stage clinical trials. Drugs that fail to induce disease regression in most patients or prolong median progression-free survival (PFS) are deemed inactive and often abandoned, even when the drug exhibits profound activity in a small number of patients. We hypothesized that sequencing the tumor genomes of such “outlier” patients might identify unique somatic alterations that are the basis of their drug response, information that could in turn inform future clinical development.

We studied the tumor genome of a patient with metastatic bladder cancer who achieved a durable (>2 years) and ongoing complete response to everolimus, a drug targeting the mTORC1 (mammalian target of rapamycin) complex (Fig. 1A). The patient was enrolled in a phase II trial (ClinicalTrials.gov NCT00805 129) that failed to achieve its PFS end point. Whole-genome sequencing of DNA derived from the primary tumor and blood (1) iden-

tified 17,136 somatic missense mutations and small insertions and deletions (mutation rate of 6.21 per million bases). Of these, 140 were non-synonymous mutations within protein-coding or noncoding RNA regions of the genome. Structurally, this tumor genome was intact, lacking significant copy number alterations or functional translocations (Fig. 1B). Among confirmed coding mutations were (i) a two-base-pair deletion in the *TSC1* (tuberous sclerosis complex 1) gene, resulting in a frameshift truncation (c.1907\_1908del, p.Glu636fs), and (ii) a nonsense mutation in the *NF2* (neurofibromatosis type 2) gene, creating a premature stop codon (c.863C>G, p.Ser288\*). These loss-of-function mutations were noteworthy (table S1) because alterations in these genes have been associated with mTORC1 dependence in preclinical models (2). Sequencing of both genes in a second cohort of 96 high-grade bladder cancers identified five additional somatic *TSC1* mutations, whereas no additional *NF2* mutations were detected (fig. S1). Although the *NF2* muta-

tion was uncommon in bladder cancers, knock-down of *NF2* expression in *TSC1*-null bladder cancer cells was associated with enhanced sensitivity to mTORC1 inhibition (fig. S1).

Because *TSC1* is mutated in a subset of bladder cancers (3), we explored whether *TSC1* mutation is a biomarker of clinical benefit from everolimus therapy in this disease. We thus analyzed 13 additional bladder cancer patients treated with everolimus in the same trial with a targeted deep sequencing assay designed to interrogate the coding exons of ~200 genes commonly mutated in human cancers [(1) and fig. S1]. This analysis revealed three additional tumors harboring nonsense mutations in *TSC1*, including two patients who had minor responses to everolimus (Fig. 1C; 17 and 24% tumor regression). A fourth patient with 7% tumor regression had a somatic missense *TSC1* variant of unknown functional consequence. In contrast, tumors from eight of the nine patients showing disease progression were *TSC1* wild type. Patients with *TSC1*-mutant tumors remained on everolimus longer than those with wild-type tumors (7.7 versus 2.0 months,  $P = 0.004$ ) with a significant improvement in time to recurrence (4.1 versus 1.8 months; hazard ratio = 18.5, 95% confidence interval 2.1 to 162,  $P = 0.001$ ).

These results suggest that mTORC1-directed therapies may be most effective in cancer patients whose tumors harbor *TSC1* somatic mutations (4) and demonstrate the feasibility of using whole-genome and capture-based sequencing methodologies in the clinical setting to identify previously unrecognized biomarkers of drug response in genetically heterogeneous solid tumors. Although single-patient anecdotes are often dismissed as failing to provide meaningful clinical evidence, this example illustrates the potential for such cases to inform future clinical development of drugs in molecularly defined populations.

## References and Notes

- Materials and methods are available as supplementary materials on Science Online.
- M. A. López-Lago, T. Okada, M. M. Murillo, N. Socci, F. G. Giancotti, *Mol. Cell. Biol.* **29**, 4235 (2009).
- F. M. Platt *et al.*, *Clin. Cancer Res.* **15**, 6008 (2009).
- D. A. Krueger *et al.*, *N. Engl. J. Med.* **363**, 1801 (2010).

**Acknowledgments:** D.F.B. is a paid consultant for Novartis, which markets everolimus. M.F.B. is a paid consultant for Foundation Medicine, a company specializing in personalized cancer medicine. The compressed binary Sequence Alignment/Map files (BAM) have been deposited in dbGaP (accession no. phs000535.v1.p1).

## Supplementary Materials

www.sciencemag.org/cgi/content/full/science.1226344/DC1

Materials and Methods

Fig. S1

Table S1

References (5–21)

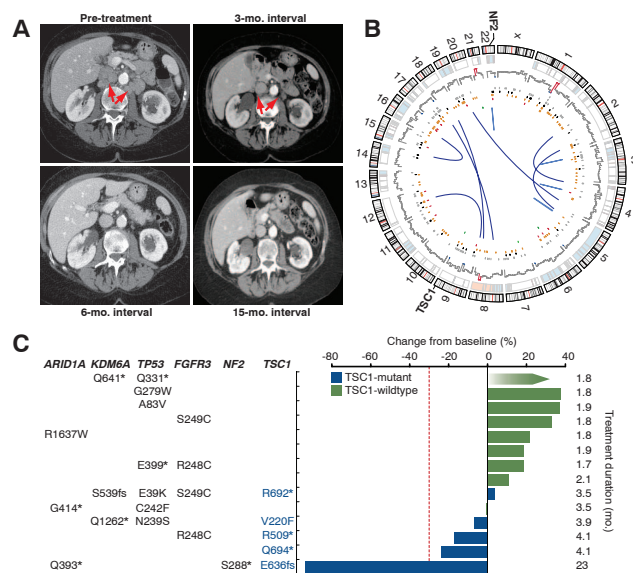
20 June 2012; accepted 13 August 2012

Published online 23 August 2012;

10.1126/science.1226344

\*The full list of author affiliations is included in the supplementary materials.

†To whom correspondence should be addressed. E-mail: barry.taylor@ucsf.edu (B.S.T.); solitd@mskcc.org (D.B.S.)



**Fig. 1. (A)** Computed tomography images of the index patient demonstrating complete resolution of metastatic disease (arrows). **(B)** Somatic abnormalities in the outlier responder's genome included (from outside to inside) copy number alterations; mutations at ~10-Mb resolution; regulatory, synonymous, missense, nonsense, nonstop, and frameshift insertion and deletion mutations (black, orange, red, green, and dark green); and intra- and interchromosomal rearrangements (light and dark blue). **(C)** Best overall response of 14 sequenced trial patients. Negative values indicate tumor shrinkage (red line, threshold for partial response). Gradient arrow, patient with rapid progression in bone.